

Colorectal anastomotic leakage corrected by transanal laparoscopy

G. Dapri, D. Guta, K. Grozdev, L. Antolino, N. Bachir, K. Jottard and G.-B. Cadière

Department of Gastrointestinal Surgery, European School of Laparoscopic Surgery, Saint-Pierre University Hospital, Brussels, Belgium

Received 13 October 2015; accepted 18 February 2016; Accepted Article online 20 April 2016

Abstract

Aim Interest in transanal laparoscopy has increased in the last decade. This approach can allow primary procedures such as polypectomy, total mesorectal excision and the treatment of postoperative complications such as bleeding, leakage and fistula formation.

Method Two patients treated by transanal repair for leakage of a colorectal anastomosis after laparoscopic anterior resection of the rectum are reported. The first developed leakage immediately during the surgery and in the second leakage presented at 4 weeks. A new transanal platform according to DAPRI (Karl Storz-Endoskope, Tuttlingen, Germany), formed by a reusable port and reusable monocurved instruments was developed to permit manipulation of sutures introduced via the anus in a maximally ergonomic manner. Laparoscopic suturing was performed transanally and a protective ileostomy was added as well.

Results The transanal procedures took 60 and 45 min and the patients were discharged after 5 days and 2 days. At 2 months both defects were found to be healed on contrast radiology and endoscopy; therefore the ileostomy was closed. Anal function was satisfactory with a frequency of two and one times per 24 h with no incontinence or evidence of sepsis.

Conclusion Intra-operative or late leakage of colorectal anastomosis can be safely treated by transanal laparoscopy. This new transanal platform offers the surgeon the possibility to work in ergonomic positions, without increasing the cost of the procedure thanks to the reusable nature of the material used.

Keywords Transanal, colorectal leaks, minimally invasive surgery, laparoscopy, TME

Introduction

Transanal laparoscopy, described in 1983 for the local excision of benign and early malignant lesions [1], has been re-evaluated especially for down-to-up total mesorectal excision [2]. Colorectal anastomosis is commonly performed using a stapler or a handsewn technique [3]. Leakage of the anastomosis has an incidence of 0%–23% [4]. Treatment depends on the size of the defect and the condition of the patient. Leakage appearance can be at the time of surgery, a few days after the operation or later during follow-up. Treatment can be conservative using parenteral nutrition and antibiotics,

diversion of the faecal stream or endoluminal vacuum therapy [5].

In this report, a new method is described for the treatment of colorectal anastomotic leakage using transanal laparoscopy. The approach can also be used for bleeding [6] or stenosis [7]. The technique reported allows control of the defect without increasing the cost of the procedure, given the inexpensive nature of the material used. Moreover, it allows the surgeon to work easily with ergonomically designed instruments, but a learning curve is required to achieve familiarity with this technique [8].

Method

The first patient was a 50-year-old female presenting with a rectal adenocarcinoma at 8 cm from the anal margin. It was treated by neoadjuvant chemoradiation followed by laparoscopic anterior resection of the rectum (LARR) using a circular mechanical 29-mm stapler for the colorectal anastomosis. The intra-operative air

Correspondence to: Giovanni Dapri, MD, PhD, FACS, Department of Gastrointestinal Surgery, European School of Laparoscopic Surgery, Saint-Pierre University Hospital, 322 Rue Haute, 1000 Brussels, Belgium.
E-mail: giovanni@dapri.net

This paper was presented as video at the 10th Annual Meeting of the European Society of Coloproctology (ESCP) on 23–25 September 2015 in Dublin, Ireland.

Figure 1 Reusable transanal port according to DAPRI (a) and DAPRI reusable monocurved instruments: grasping forceps (b), coagulating hook (c), needle holder (d), scissors (e), suction and irrigation cannula (f) (Source: Karl Storz – Endoskope, Tuttlingen, Germany).

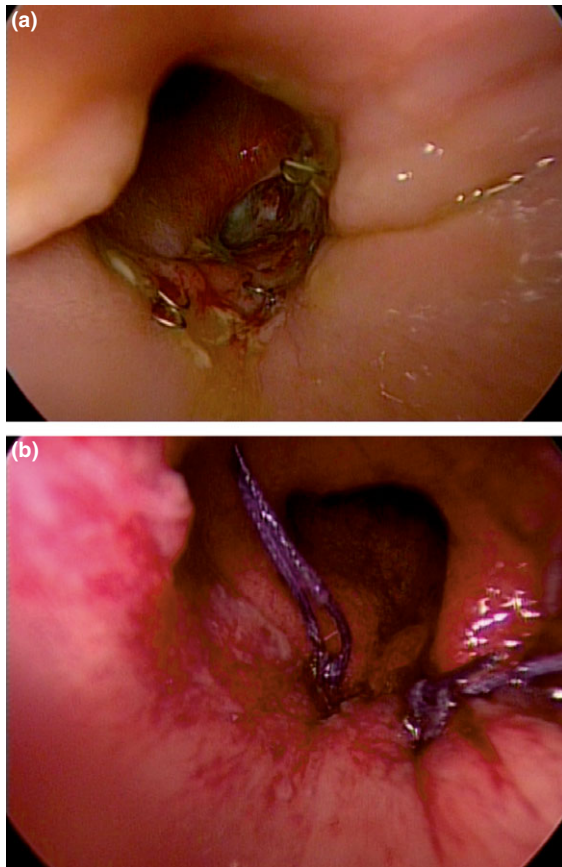



Figure 2 Late colorectal fistula: endoluminal exposure (a) and final closure (b).

test was positive and a posterior defect in the anastomosis was found at 4 cm from the anal margin. A transanal repair was performed and a protective diverting loop ileostomy was constructed.

The second patient was a 65-year-old male treated by neoadjuvant chemoradiation and LARR using the

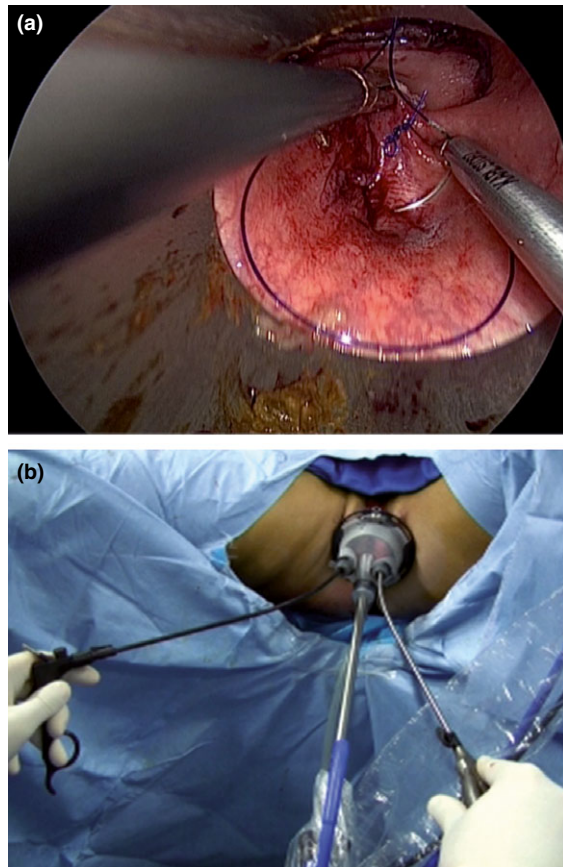


Figure 3 Immediate colorectal leak: endoluminal suture (a) and surgeon's ergonomics (b).

same stapler for a rectal cancer at 15 cm from the anal margin. He was discharged after 5 days and during follow-up he developed anastomotic leakage seen at 4 weeks to be located posteriorly at 11 cm from the anal margin. A transanal repair was carried out together with a protective diverting loop ileostomy.

Surgical technique

The patient was placed in the Lloyd-Davies position and a reusable transanal D-Port according to DAPRI (Karl Storz – Endoskope) (Fig. 1a), was introduced into the anus and fixed to the skin by four cardinal sutures. A three-orifice silicone cap was applied to the port and CO₂ was insufflated into the rectal lumen. A 10-mm, 30° rigid scope (Karl Storz – Endoskope) was introduced into the central orifice and the 5-mm reusable monocular instruments according to DAPRI (Karl Storz – Endoskope), such as grasping forceps (Fig. 1b), were introduced through the 9 o'clock orifice, while a coagulating hook (Fig. 1c), needle holder (Fig. 1d), scissors (Fig. 1e), and suction and irrigation cannula (Fig. 1f) were inserted through the 3 o'clock orifice.

The defect was identified (Fig. 2a) and figure-of-eight endoluminal sutures (Fig. 2b) or a short running suture with a preformed knot (Fig. 3a) were inserted. The surgeon worked with the grasping forceps and the needle holder under good ergonomic conditions (Fig. 3b) owing to the curve of the instrument. Endoluminal suturing and knotting were easy to perform and permitted closure of the defect.

Results

The transanal procedures took 60 and 45 min with no intra-operative bleeding. The hospital stay was 5 and 2 days. Clinical examination at 2 months followed by a contrast enema and colonoscopy showed complete healing of the fistula without any evidence of stenosis; therefore the ileostomy was closed. Anal function was satisfactory with a frequency of two and one times every 24 h with no incontinence or evidence of sepsis.

Discussion

Transanal laparoscopy has gained interest especially for down-to-up total mesorectal excision [9]. The advantages of transanal laparoscopy include a magnified operative field and improved exposure, and the authors started to adopt this approach for complications such as anastomotic defects. This application was first reported for the repair of the rectourethral fistula by transanal endoscopic microsurgery [10]. In the first case reported here, this approach avoided the development of a postoperative fistula and the consequent difficult management of the leakage [11], with discharge from hospital at 5 days. Hence, on detecting leakage on the air test, the surgeon can perform transanal laparoscopy rather than using a more invasive approach to close it. In the case of the second patient, the

transanal approach allowed successful closure again without more invasive surgery and with rapid discharge from hospital. Clearly the surgeon's learning curve is an important factor and he or she must be familiar with single-port surgery and be competent to work in a confined space.

In the technique reported here, the surgeon's ability to manipulate the instruments in an ergonomically satisfactory manner with curved instruments and triangulation allowed the insertion of endoluminal sutures and ligation techniques, similar to those performed by conventional laparoscopy. The use of faecal diversion is open to discussion, because other authors have reported healing of anastomotic leakage without a protective stoma [12]. It is a considerable advantage that the technique did not add any cost because the port and instruments were reusable.

In conclusion, intra-operative anastomotic defect after stapling and late anastomotic leakage can be safely treated by transanal laparoscopy. This new transanal platform allows working in a small space under ergonomic conditions, without increasing the cost of the procedure owing to the reusable nature of the instruments.

Author contributions

Study conception and design: G. Dapri. Acquisition of data: D. Guta, L. Antolino, N. Bachir. Analysis and interpretation of data: G. Dapri, K. Grozdev, K. Jottard, G.-B. Cadière. Writing of the manuscript: G. Dapri.

Conflicts of interest

G. Dapri is a consultant for Karl Storz – Endoskope, Tuttlingen, Germany. The other authors have no conflict of interest.

References

- 1 Buess G, Theiss R, Hutterer F *et al.* Transanal endoscopic surgery of the rectum – testing a new method in animal experiments. *Leber Magen Darm* 1983; **13**: 73–7.
- 2 Zorron R, Phillips HN, Wynn G, Neto MP, Coelho D, Vassallo RC. Down-to-up transanal NOTES total mesorectal excision for rectal cancer: preliminary series of 9 patients. *J Minim Access Surg* 2014; **10**: 144–50.
- 3 Lipski D, Dapri G, Himpens J. Completely staple-free hand-sewn laparoscopic anastomosis in colorectal surgery. *J Laparoendosc Adv Surg Tech A* 2008; **18**: 282–5.
- 4 Hotta T, Yamaue H. Laparoscopic surgery for rectal cancer: review of published literature 2000–2009. *Surg Today* 2011; **41**: 1583–91.

- 5 Arezzo A, Miegge A, Garbarini A, Morino M. Endoluminal vacuum therapy for anastomotic leaks after rectal surgery. *Tech Coloproctol* 2010; **14**: 279–81.
- 6 Bravo R, Fernandez-Hevia M, Jimenez-Toscano M, de Lacy B, Delgado S, Lacy AM. TAMIS a new option for the treatment of postoperative haemorrhage. *Colorectal Dis* 2015; **17**: 105.
- 7 Baatrup G, Svensen R, Ellensen VS. Benign rectal strictures managed with transanal resection – a novel application for transanal endoscopic microsurgery. *Colorectal Dis* 2010; **12**: 144–6.
- 8 Barendse RM, Dijkgraaf MG, Rolf UR *et al.* Colorectal surgeons' learning curve of transanal endoscopic microsurgery. *Surg Endosc* 2013; **27**: 3591–602.
- 9 Dapri G, Grozdev K, Guta D, Cadière GB. Down-to-up transanal rectal resection with total mesorectal excision assisted by single-incision laparoscopy. *Colorectal Dis* 2016; **18**: 517–8.
- 10 Wilbert DM, Buess G, Bichler KH. Combined endoscopic closure of rectourethral fistula. *J Urol* 1996; **155**: 256–8.
- 11 Rickert A, Willeke F, Kienle P, Post S. Management and outcome of anastomotic leakage after colonic surgery. *Colorectal Dis* 2010; **12**: e216–3.
- 12 Beunis A, Pauli S, Van Cleemput M. Anastomotic leakage of a colorectal anastomosis treated by transanal endoscopic microsurgery. *Acta Chir Belg* 2008; **108**: 474–6.

Supporting Information

Additional Supporting Information may be found in the online version of this article:

Video S1. Colorectal leaks correction (<https://www.youtube.com/watch?v=NAOQ0QKQOFg>).